Vertical Gastric Bypass with Fundectomy: Feasibility and 2-Year Follow-Up in a Series of Morbidly Obese Patients

Marco Antonio Zappa, Alberto Aiolfi, Cinzia Musolino, Maria Paola Giusti, Giovanni Lesti & Andrea Porta

Obesity Surgery
The Journal of Metabolic Surgery and Allied Care

ISSN 0960-8923
Volume 27
Number 8

OBES SURG (2017) 27:2145-2150
DOI 10.1007/s11695-017-2620-y

Springer

OBES SURG (2017) 27:2145–2150
DOI 10.1007/s11695-017-2620-y

ORIGINAL CONTRIBUTIONS

Vertical Gastric Bypass with Fundectomy: Feasibility and 2-Year Follow-Up in a Series of Morbidly Obese Patients

Marco Antonio Zappa[1] · **Alberto Aiolfi**[1] · **Cinzia Musolino**[1] · **Maria Paola Giusti**[1] · **Giovanni Lesti**[2] · **Andrea Porta**[1]

Published online: 7 March 2017

Abstract
Background Roux-en-Y gastric bypass (RYGB) is the gold standard procedure for morbid obesity and its results are well known and largely discussed. The major limitation of the procedure is the difficult exploration of the excluded gastric pouch and duodenum. The vertical gastric bypass with fundectomy was recently introduced in attempt to overcome these limitations. To date, its effectiveness is debated and outcomes still unclear. The purposes of this study were to describe the vertical gastric bypass with fundectomy and to analyse its outcomes in term of weight loss, complications, and comorbid resolutions.
Material and Methods Since January 2012 to July 2014, 30 consecutive patients were enrolled and prospectively followed for a 24-month period. All patients underwent the vertical gastric bypass with fundectomy. Follow-up visits were scheduled at 7 days, 1, 6, 12, and 24 months, or whenever necessary.
Results Overall, 24 women and six men were enrolled in the study. Mean preoperative BMI was 38.2 ± 8.5 kg/m^2. No intraoperative complications were reported. Postoperative overall complication rate was 10%. Compliance to the 24-month follow-up was 100%. Mean BMI and excess weight loss (EWL%) were significantly lower compared to baseline ($p < 0.05$). Comorbid improvement or resolution was recorded in the 80% of the patients.
Conclusions Vertical gastric bypass with fundectomy is feasible and effective with similar results in terms of weight loss, complications, and comorbid improving compared to the classic RYGB. Complete evaluation of the gastric anatomy and easy access to the main duodenal papilla are unquestionable advantages.

Keywords Bariatric surgery · Vertical gastric bypass · Gastric fundectomy · Ghrelin · Outcomes

✉ Marco Antonio Zappa
marcoantoniozappa@libero.it

Alberto Aiolfi
alberto.aiolfi86@gmail.com

Cinzia Musolino
cinziamusolino@gmail.com

Maria Paola Giusti
paola083@tin.it

Giovanni Lesti
giovannilesti@tin.it

Andrea Porta
andrea.porta72@gmail.com

[1] Department of General and Emergency Surgery, University of Milan, Ospedale Fatebenefratelli "Sacra Famiglia", Via Fatebenefratelli n.20, Erba, CO, Italy

[2] Department of General Surgery, Fondazione Salus Clinica Di Lorenzo, Via Vittorio Veneto n 37, Avezzano, AQ, Italy

Introduction

The Roux-en-Y gastric-bypass (RYGB) is the most popular surgical procedure for morbid obesity because of its standardization and its excellent results in terms of weight loss, metabolic syndrome improvement, and comorbid resolution [1]. Its effectiveness is determined by reduction of the overall gastric volume combined with consensual orexigenic peptide secretions [2]. Major limitations of this technique are the arduous diagnosis and treatment of burning disease in the remnant gastric pouch and duodenum.

Different techniques have been previously described in attempt to overcome these limitations. The vertical gastric

bypass with fundectomy consists in a laparoscopic vertical gastric bypass with gastric fundus resection. A Gore-Tex® band is placed to reduce the outlet from the gastric pouch diverting the bolus towards the jejunal loop. This technique overwhelms the RYGB anatomic limitation allowing complete gastric and duodenal endoscopic evaluation [3]. Outcomes in term of weight loss, overall complications, and comorbid resolution are still unclear and widely debated.

The purposes of this study were to describe the laparoscopic vertical gastric bypass technique and prospectively analyse the outcomes in a series of morbidly obese patients.

Material and Methods

From January 2012 to June 2014, 30 consecutive patients underwent the vertical gastric bypass with fundectomy and were prospectively followed for a 2-year period. Follow-up visits were scheduled at 7 days 1, 6, 12, and 24 months, or whenever necessary.

Perioperative Evaluation

All patients were studied with the following preoperative tests: oral glucose load curve and glycaemic status, C-peptide and Hb1Ac dosages, lipidic profile, chest X-ray, cardiological evaluation, spirometry with blood gases analysis, dietician evaluation, psychological eating behaviour evaluation, gastroscopy with biopsy to rule out helicobacter pylori, and abdominal ultrasound. Prophylactic cholecystectomy was not performed if there was no evidence of stones or sludge in the gallbladder lumen.

Surgical Technique

The patient is positioned in the supine position with open legs in the anti-Trendelenburg position. The first surgeon stays in the middle, the second surgeon to the right, and the third to the left of the patient. Under general anaesthesia, the pneumoperitoneum is established via a left subcostal Verres needle. Five trocars are positioned under direct view. The optical trocar is placed at the abdominal midline approximately 5–6 fingerbreadths from the xiphoid process. A 5-mm sub-xiphoid trocar is placed for liver retraction. Two 12-mm ports are placed on the mid-clavicular line on the right and left flank for operative instruments. A 5-mm trocar is further placed on the right lateral subcostal space.

The gastrocolic ligament is opened at the greater curve (Van Goethem's point) to enable access into the lesser sac and the gastric fundus is freed. An orogastric 36Fr bougie is advanced for gastric pouch calibration and fundectomy is performed with a linear laparoscopic stapler (EndoGIA®) (Fig. 1). A Gore-Tex® mesh, calibrated over the 36Fr bougie, is placed 7 cm below the cardia and fixed with an unabsorbable braided wire (Fig. 2). The bypass is performed with the dual loop technique in an antecolic route. The gastrojejunal anastomosis is fashioned 50 cm far from the Treitz's ligament, on the lateral wall of the gastric pouch, 5 cm below the cardia (Fig. 3). The alimentary loop is anastomosed 150 cm far from the first anastomosis (Fig. 4). Enterotomies are closed with interrupted absorbable sutures (Vicryl 4/0®). A drainage is placed close to the anastomosis. During the procedure, a nasogastric tube (NGT) was placed and an intraoperative methylene blue dye test was performed to rule out early leak.

Preoperative antibiotic prophylaxis is given with Cephalosporin (2 g) and Metronidazole (500 mg). Omeprazole (40 mg) is given till 30th postoperative day. In the first postoperative day, a methylene blue dye test is performed and if negative the patient allowed to resume a clear diet. At discharge, an oral vitamin support is introduced.

Statistical Analysis

Continuous variables were reported as means with standard deviation interval (SD). The Mann-Whitney U test was used to compare means for continuous data points. Variables with p value <0.05 were considered significant. All statistical analysis was performed using SPSS for windows version 23.0 (SPSS Inc. Chicago, IL).

Results

Overall, 30 consecutive patients underwent the vertical gastric bypass with fundectomy during the study period. The 93% of patients (n = 28) underwent a primary procedure and 7% (n = 2) underwent a revisional procedure. Previous surgical operations were a gastric band (n = 1) and a sleeve gastrectomy (n = 1). In case of revisional surgery, the elapsed time from index operation was 3 months in both cases. Twenty-four patients (80%) were women and six (20%) were men. Mean age of the study population was 38 ± 3.1 years old. Preoperative mean BMI was 38.2 ± 8.5 kg/m^2. Three patients (10%) had preoperative hypertension requiring medications and three patients (10%) had diabetes requiring insulin therapy (n = 1) or oral therapy (n = 2). Five patients (16.5%) had dyslipidaemia under statin treatment (Table 1).

Two senior surgeons experienced in laparoscopic surgery (ZM, PA) performed all the procedures. Mean operative time was 126 ± 14 min. No major intraoperative complications were observed, intraoperative blood loss was negligible, and no laparotomy conversion was required. The overall complication rate, considering both early and late development, was 10%. In one case, the postoperative course was complicated by gastric anastomosis bleeding on the second postoperative

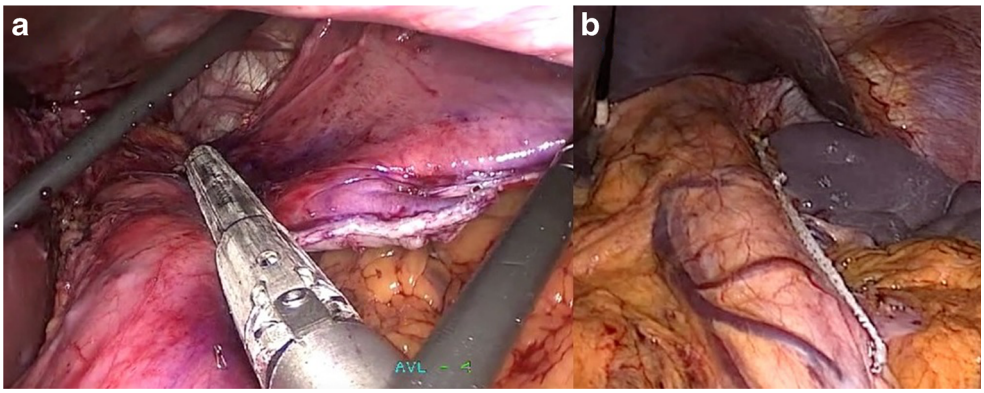

Fig. 1 A vertical gastric fundecotmy is calibrated over a 36Fr orogastric bougie with a linear laparoscopic stapler (EndoGIA®)

day. Endoscopic management was successful and two haemostatic clips were deployed. The patient was discharged on the eighth postoperative day. In two cases, a post-incisional trocar site hernia required a laparoscopic revision, respectively in the eighth and 61st postoperative days. The postoperative course was uneventful in both patients. Overall, mean postoperative in-hospital length of stay was 4 ± 3 days with no difference between non-complicated and complicated patients ($p = 0.083$). None of the patients required postoperative ICU monitoring nor postoperative mechanical ventilator assistance. There was no mortality in the study group.

Compliance to the 24-month follow-up was 100%. An endoscopic evaluation was performed in all patients at 12 and 24 months. In one patient, an ERCP with sphincterotomy was performed for choledocolithiasis 18 months after the index procedure. Mean BMI at 6, 12, and 24 months was 35.6 ± 6.9 , 34.1 ± 5.7, and 33.2 ± 5.4 kg/m^2, respectively. Excess weight loss (EWL%) was 51.6 ± 13.9% at 6-month follow-up, 61.7 ± 10.4% at 12-month, and 64.5 ± 11.9% at 24-month follow-up (Table 2). Mean BMI and EWL% at 24-month follow-up were all significantly improved compared to baseline ($p < 0.05$). One year after surgery, serum cholesterol level, low-density lipoprotein (LDL), and triglycerides were significantly decreased. At 2-year follow-up, improvement or resolution was observed in diabetic patients with suspension ($n = 2$) or reduction ($n = 1$) of the daily hypoglycaemic or insulin therapy. Hypertension was resolved in all patients, and improvement in lipid profile was observed in the 65% of patients.

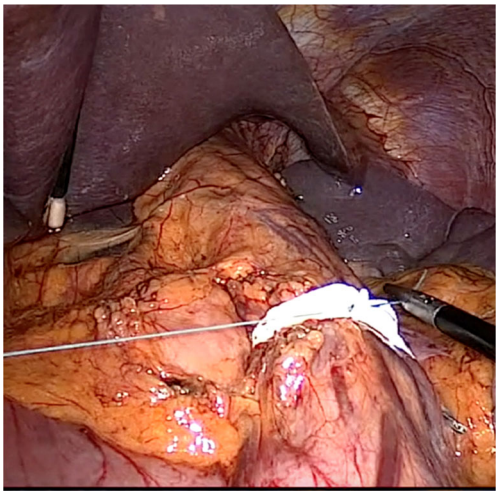

Fig. 2 A Gore-Tex® mesh is placed 7 cm below the cardia and fixed with an unabsorbable braided wire

Discussion

In 1976, Mason et colleagues first described the gastric bypass technique for morbid obesity [4]. Since then, multiple technical adjustments have been proposed to the original procedure always maintaining excellent results in terms of weight loss and comorbid resolution. Nowadays, the laparoscopic RYGB is the most common operation performed in the USA and the gold standard procedure for morbid obesity [5]. Major limitation is the difficult endoscopic access to the excluded stomach and duodenum for diagnostic and treatment procedures [6]. Mucosal bleeding, gastric ulcer, perforation, and cancer in the remnant stomach have been described as potential life-

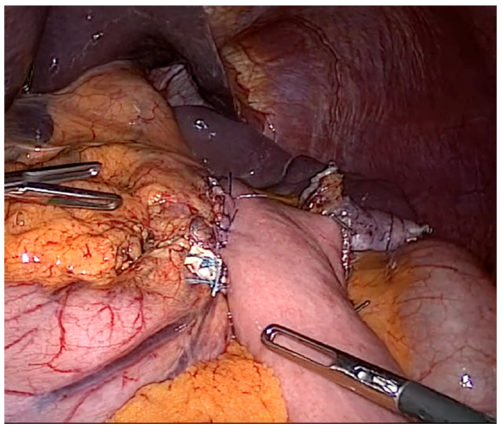

Fig. 3 The gastrojejunal anastomosis is created on the lateral wall of the gastric pouch, 5 cm below the cardia

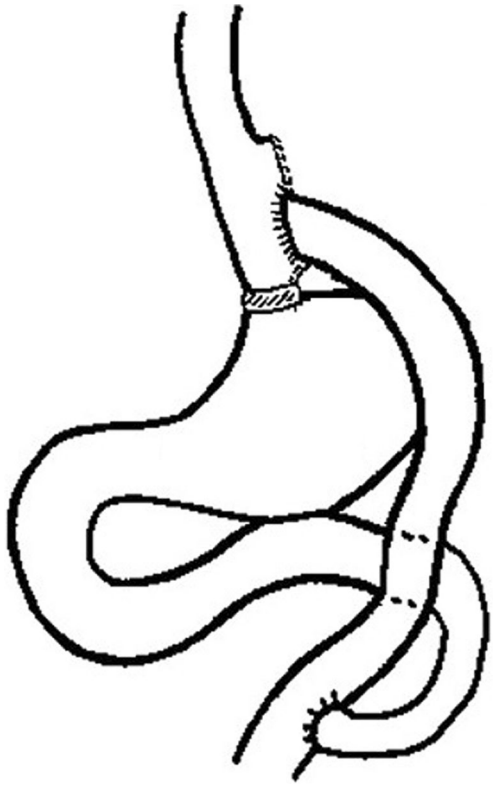

Fig. 4 The side-to-side gastrojejunal anastomosis is fashioned 5 cm below the cardia. The alimentary loop is anastomosed 150 cm below the first anastomosis

threatening complications [7–11]. Moreover, the incidence of cholelithiasis and choledocolithiasis after RYGB ranges from 27 to 38% [12, 13]. Surgical avulsion of the vagal hepatic branch, an altered enteric stimulation, changes in the gallbladder mucin production, and the modified bile salt/cholesterol ratio are possible causes of this phenomenon [14–16]. Standard ERCP, sphincterotomy, and drainage of the common bile duct are extremely arduous in these patients [17]. A prophylactic cholecystectomy has been proposed by some colleagues but to date the issue is still extensively debated.

Table 1 Baseline characteristics of the study population. Data are presented as mean ± standard deviation and *n* (%)

	Demographics
Age (years)	38 ± 3.1
Female/male ratio	24/6
BMI (Kg/m^2)	38.2 ± 8.5
History of binge eating	2 (6.6%)
Smoking history (past/current)	9 (30%)
Comorbidities	
Diabetes	3 (10%)
Hypertension	3 (10%)
Dyslipidemia	5 (16.7%)
OSAS	1 (3.3%)
Joint pain	7 (23.3%)
Preoperative Hb (g/dl)	14.2 ± 1.6
Preoperative Alb (g/dl)	4.3 ± 0.6

Table 2 Change in body mass index (BMI) and percentage of excess weight loss (EWL%) at different follow-up time. All the parameters at 24-month follow-up were significantly different compared to baseline ($p < 0.05$). Data are presented as mean ± standard deviation

	BMI (Kg/m^2)	EWL%
Pre-operative	38.2 ± 8.5	49.2 ± 10.8
6 months	35.6 ± 6.9	51.6 ± 13.9
12 months	34.1 ± 5.7	61.7 ± 10.4
24 months	33.2 ± 5.4	64.5 ± 11.9

For these reasons, Cariani et al. first introduced a new laparotomic RYGB by creating a 30-cm^3 vertical gastric pouch using a 25-mm circular transgastric stapler. The gastric pouch was then encircled by a Gore-Tex® band, leaving a gastric outlet of 1 cm inside diameter. The technique allowed a complete gastric and duodenal endoscopic evaluation [18, 19]. Mozzi and colleagues first performed the Cariani's Roux-en-Y gastric bypass on vertical banded gastroplasty in a minimally invasive fashion [20]. In 2009, Lesti et al. introduced the innovative concept of a vertical gastric bypass with fundectomy [3, 21]. The fundectomy overcome the arduous use of the transgastric circular stapler described by Cariani and the jejunoileal anastomosis was fashioned 200-220 cm below the first anastomosis. In our series, the gastrojejunal side-to-side anastomosis was fashioned with a linear laparoscopic stapler and the jejunoileal anastomosis performed 150 cm below the first anastomosis [22]. The linear laparoscopic stapler is associated with a reduced risk of anastomotic stenosis, postoperative infections, and overall operative time with similar postoperative leak rate compared to the circular stapler [23]. It has been proven that the gastric fundus plays a significant role on ghrelin secretion and metabolism. Ghrelin physiology is characterized by a rise during fasting periods and a rapid postprandial fall. In obese patients, fasting ghrelin levels are elevated and dynamics are altered with a missing postprandial inhibition [24–26]. The reductions of ghrelin secretion together with its serum concentration are achieved after the vertical gastric bypass with fundectomy [27].

In this study, we report our initial experience with the vertical gastric bypass and fundectomy in morbid obese patients. The overall rate for early and late complications was 10% and a significant postoperative bleeding, requiring endoscopic management, occurred in one patient (3%). Similar results have been described in previous RYGB reviews with a 2% bleeding complication rate in the first 2-year follow-up [28, 29]. In accordance with Kellogg and colleagues in our study, the incidence of postoperative incisional hernia was 6.5% [30]. Compared to baseline, a significant improvement of initial BMI and EWL% was recorded at 24-month follow-up.

Although limited, these data are in accordance with O'Brien et al. and Magro and colleagues that reported similar data on RYGB weight loss in the short-term period [31, 32]. In line with a 2014 meta-analysis published by Li and colleagues, a significant comorbid improvement or resolution was observed in the 80% of patients [33]. In our series, we do not experience any episode of band erosion, dislocation, and marginal ulcers. In this direction, Cariani and colleagues reported a 0% incidence of banding erosion/dislocation and a 0.7% of marginal ulcer occurrence at a 4-year follow-up [19]. These events should be considered as possible complications especially in the long-term period. Adequate PPI therapy, smoke suspension, and endoscopic surveillance in case of suspicious symptoms onset are advisable.

The incidence of gastrogastric fistula after RYGP is a rare, well-known complication that may affect the metabolic outcomes [34]. Staple line ischemia, necrosis, inflammatory processes, marginal ulcers, and increased intraluminal pouch pressure are all possible determining factors. Differently, we believe that the concept behind the gastrogastric anastomosis is diverse being the result of a specific and well-calibrated surgical procedure. Moreover, the location and the clinical expression are extremely dissimilar being the gastrogastric fistula proximal to the gastrojejunal anastomosis and usually associated with an early sense of satiety and failed weight loss. With the vertical gastric bypass, an almost complete functional duodenal exclusion is achieved. As documented by the gastrografin swallow study, the majority of the food intake passes through the gastrojejunal anastomosis (Fig. 5). This is attributable to a physiologic gastric emptying mechanism combined with the reduced gastrogastric communication.

To our knowledge, this is the first prospective observational study on a series of morbidly obese patients treated with the vertical gastric bypass and fundectomy. The technique is surgically demanding, it requires major expertise in laparoscopic and bariatric surgery, and should be performed in referral center. This technique allows a complete endoscopic gastric exploration with a standard 9-mm endoscope and any procedure on the common bile duct with a regular 11-mm duodenoscope. In the long-term follow-up, a reduction in the incidence of postprandial hypoglycaemia could be another potential advantage compared to the classic RYGP. Moreover, its prospective nature and the 100% compliance at 2-year follow-up enhance the strength of the study.

Limitations are the narrow population and the short-term follow-up. The occurrence of band erosion, dislocation, infection, stenosis, and the development of marginal ulcer should be investigated. Moreover, the long-term effect on diabetes remission, comorbid resolution, and weight loss should be addressed in further studies.

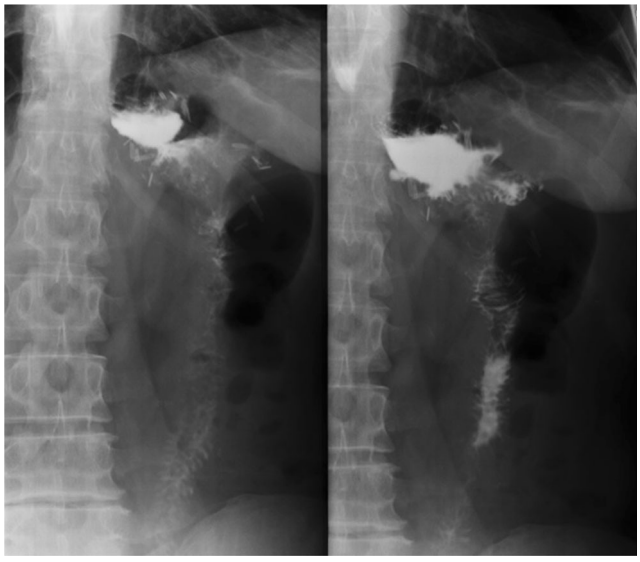

Fig. 5 Gastrografin swallow study. Near all of the contrast passes through the gastrojejunal anastomosis

Conclusions

The vertical gastric bypass with fundectomy is feasible and effective in terms of weight loss and comorbid resolution being a valid alternative to the standard RYGB. Major advantage of this technique is the exploration of the excluded stomach and access to the Vater's papilla. Further multicentre prospective studies are required in order to validate our findings.

Acknowledgements The authors thank Brent Maddock for his help with language corrections.

Authors' Contribution A.A and C.M. did the literature search.
M.A.Z. and A.A formed the study design.
Data collection done by A.A, C.M, M.P.G.
M.A.Z, A.A, and G.L analysed the data.
M.A.Z, A.A, G.L, and A.P interpreted the data.
A.A wrote the manuscript.
M.A.Z, G.L, and A.P critically reviewed the manuscript.

Compliance with Ethical Standards All procedures performed in studies involving human participants were in accordance with the ethical standards of the institutional and/or national research committee and with the 1964 Helsinki Declaration and its later amendments or comparable ethical standards.

Conflict of Interest The authors declare that they have no conflict of interest.

Informed Consent Informed consent was obtained from all individual participants included in the study.

References

1. Buchwald H, Avidor Y, Braunwald E, et al. Bariatric surgery: a systematic review and meta-analysis. JAMA. 2004;292:1724–37.

2. Svane MS, Jørgensen NB, Bojsen-Møller KN, et al. Peptide YY and glucagon-like peptide-1 contribute to decreased food intake after Roux-en-Y gastric bypass surgery. Int J Obes. 2016;40: 1699–706.
3. Lesti G, Tidona V, Lanci C, et al. Bypass gastrico laparoscopico con fundectomia e stomaco esplorabile secondo Lesti. Tecnica e follow-up a sei anni. Ospedali D'Italia. 2009;15:440.
4. Mason EE, Ito C. Gastric bypass in obesity. Surg Clin North Am. 1967;47:1345–51.
5. Lim RB, Blackburn GL, Jones DB. Benchmarking best practices in weight loss surgery. Curr Probl Surg. 2010;47:79–174.
6. Facchiano E, Quartararo G, Pavoni V, et al. Laparoscopy-assisted transgastric endoscopic retrograde cholangiopancreatography (ERCP) after Roux-en-Y-gastric bypass: technical features. Obes Surg. 2015;25:373–6.
7. Papasavas PK, Yeaney WW, Caushaj PF, et al. Perforation in the bypassed stomach following laparoscopic Roux-en-Y gastric bypass. Obes Surg. 2003;13:797–9.
8. Gypen BJ, Hubens GJ, Hartman V, et al. Perforated duodenal ulcer after laparoscopic gastric bypass. Obes Surg. 2008;18:1644–6.
9. Harper JL, Beech D, Tichansky DS, et al. Cancer in the bypassed stomach presenting early after gastric bypass. Obes Surg. 2007;17: 1268–71.
10. Orlando G, Pilone V, Vitiello A, et al. Gastric cancer following bariatric surgery: a review. Surg Laparosc Endosc Percutan Tech. 2014;24:400–5.
11. Leuratti L, Di Simone MP, Cariani S. Unexpected changes in the gastric remnant in asymptomatic patients after Roux-en-Y gastric bypass on vertical banded gastroplasty. Obes Surg. 2013;23:131–9.
12. Schneider BE, Villegas L, Blackburn GL, et al. Laparoscopic gastric bypass surgery: outcomes. J Laparoendosc Adv Surg Tech A. 2003;13:247–55.
13. Bastouly M, Arasaki CH, Ferreira JB, et al. Early changes in postprandial gallbladder emptying in morbidly obese patients undergoing Roux-en-Y gastric bypass: correlation with the occurrence of biliary sludge and gallstones. Obes Surg. 2009;19:22–8.
14. Al-Jiffry BO, Shaffer EA, Saccone GT, et al. Changes in gallbladder motility and gallstone formation following laparoscopic gastric banding for morbid obesity. Can J Gastroenterol. 2003;17:169–74.
15. Shiffman ML, Sugerman HJ, Kellum JM, et al. Gallstone formation after rapid weight loss: a prospective study in patients undergoing gastric bypass surgery for treatment of morbid obesity. Am J Gastroenterol. 1991;86:1000–5.
16. Shiffman ML, Sugerman HJ, Kellum JM, et al. Changes in gallbladder bile composition following gallstone formation and weight reduction. Gastroenterology. 1992;103:214–21.
17. Ross AS, Semrad C, Alverdy J, et al. Use of double balloon enteroscopy to perform PEG in the excluded stomach after Roux-en-Y gastric bypass. Gastrointestinal Endosc. 2006;64:797–800.
18. Cariani S, Vittimberga G, Grani S, et al. A functional Roux-en-Y gastric bypass to avoid gastric exclusion: 1-year results. Obes Surg. 2003;13:788–91.
19. Cariani S, Palandri P, Della Valle E, et al. Italian multicenter experience of Roux-en Y gastric bypass on vertical banded gastroplasty: four-year results of effective and safe innovative procedure enabling traditional endoscopic and radiographic study of bypassed stomach and biliary tract. Surg Obes Relat Dis. 2008;4:16–25.
20. Mozzi E, Lattuada E, Zappa MA, et al. Failure of gastric bypass following several gastrointestinal hemorrhages. Obes Surg. 2010;20:523–5.
21. Lucchese M, Cariani S, Amenta E, et al. Other bariatric procedures. In: Angrisani L, editor. Bariatric and metabolic surgery. Berlin: Springer; 2016. p. 195–206.
22. Cariani S, Agostinelli L, Giorgini E, et al. Roux-en-Y gastric bypass on vertical banded gastroplasty: 6 years of experience of modified gastric bypass which allows endoscopic and radiological investigation of the excluded stomach [abstract]. Obes Surg. 2009;19:1048–9.
23. Giordano S, Salminen P, Biancari F, et al. Linear stapler technique may be safer than circular in gastro-iejunal anastomosis for laparoscopic Roux en y gastric bypass: a meta-analysis of comparative studies. Obes Surg. 2011;21:1958–64.
24. Wölnerhanssen B, Peterli R. State of the art: sleeve gastrectomy. Dig Surg. 2014;31:40–7.
25. Peterli R, Steinert RE, Woelnerhanssen B, et al. Metabolic and hormonal changes after laparoscopic Roux-en-Y gastric bypass and sleeve gastrectomy: a randomized, prospective trial. Obes Surg. 2012;22:740–8.
26. Christou NV, Look D, Maclean LD. Pre-and post-prandial ghrelin levels do not related with satiety or failure to achieve a successful outcome after Roux-en-Y gastric bypass. Obes Surg. 2005;15: 1017–23.
27. Chronaiou A, Tsoli M, Kehagias I, et al. Lower ghrelin levels and exaggerated postprandial peptite YY, glucacon-like peptide-1 and insulin responses after gastric fundus resection in patients undergoing roux-en-Y gastric bypass: a randomized clinical trial. Obes Surg. 2012;22:1761–70.
28. Braley SC, Nguyen NT, Wolfe BM. Late gastrointestinal hemorrhage after gastric bypass. Obes Surg. 2002;12:404–7.
29. Mehran A, Szomstein S, Zundel N, et al. Management of acute bleeding after laparoscopic Roux-en-Y gastric bypass. Obes Surg. 2003;13:842–7.
30. Kellogg TA, Swan T, Leslie DA, et al. Patterns of readmission and reoperation within 90 days after Roux-en-Y gastric bypass. Surg Obes Relat Dis. 2009;5:416–23.
31. O'Brien PE, McPhail T, Chaston TB, et al. Systematic review of medium-term weight loss after bariatric operations. Obes Surg. 2006;16:1032–40.
32. Magro DO, Geloneze B, Delfini R, et al. Long-term weight regain after gastric bypass: a 5 years prospective study. Obes Surg. 2008;8: 648–51.
33. Li JF, Lai DD, Lin ZH, et al. Comparison of the long-term results of Roux-en-Y gastric bypass and sleeve gastrectomy for morbid obesity: a systematic review and meta-analysis of randomized and nonrandomized trials. Surg Laparosc Endosc Percutan Tech. 2014;24:1–11.
34. Ribeiro-Parenti L, De Courville G, Daikha A, Arapis K, Chosidow D, Marmuse JP. Classification, surgical management and outcomes of patients with gastrogastric fistula after Roux-En-Y gastric bypass. Surg Obes Relat Dis. 2016 Sep 28. pii: S1550–7289(16)30726–2.